

Content available at: <https://www.ipinnovative.com/open-access-journals>

IP Journal of Otorhinolaryngology and Allied Science

Journal homepage: <https://www.joas.co.in/>

Original Research Article

Mucormycosis during the COVID-19 pandemic: Our takeawaysShruti Jha¹, Mani Mala¹, Rakesh Kumar Singh^{1*}¹Dept. of ENT, Indira Gandhi Institute of Medical Sciences, Patna, Bihar, India

ARTICLE INFO

Article history:

Received 12-06-2024

Accepted 10-07-2024

Available online 02-08-2024

Keywords:

Mucormycosis

Fungal infection

Diabetes mellitus

COVID-19

ABSTRACT

Background: *Mucormycosis* is a rare, opportunistic fungal infection that affects immune-compromised hosts. When involving the PNS, it can be Rhino-orbital or Rhinocerebral and may rapidly prove fatal.

Materials and Methods: We present a retrospective case series analysis of 48 patients from the COVID-19 pandemic, our management of them, and our takeaways.

Result: Out of 48, 12 had a previous history of oxygen therapy, 32 had tested positive for COVID-19 recently, 8 had a history of ICU admission, and the most common occupations affected were homemakers and housewives. Grade 2 and 3 of rhino-orbital cerebral *mucormycosis* (ROCM) were most commonly found, and 28 developed type 2 diabetes before and after ROCM and 4 in the aftermath of the disease.

Conclusion: A high degree of suspicion should be maintained in all patients with nasal, orbital, or neuro complaints with a previous history of COVID-19 infection and with or without co-morbid conditions.

This is an Open Access (OA) journal, and articles are distributed under the terms of the [Creative Commons Attribution-NonCommercial-ShareAlike 4.0 License](https://creativecommons.org/licenses/by-nc-sa/4.0/), which allows others to remix, tweak, and build upon the work non-commercially, as long as appropriate credit is given and the new creations are licensed under the identical terms.

For reprints contact: reprint@ipinnovative.com

1. Introduction

Mucormycosis is a rare, opportunistic infection caused by saprophytic fungi of the order Mucorales. The most common agents of *mucormycosis* are *Rhizopus*, *Mucor*, and *Lichtheimia* species. *Mucormycosis* tends to affect immunocompromised patients with a long history of diabetes mellitus, COVID-19, HIV, haematological malignancies, renal transplant patients, patients on dialysis, extensive skin injury, steroid treatment and other comorbid conditions. Like other opportunistic infections, it thrives in reduced host immunity and associated environmental factors like raised blood sugar and iron overload. *Mucormycosis* can present as rhino-orbital. Rhino orbital-cerebral, pulmonary, cutaneous, intestinal and disseminated variants. *Mucormycosis* is characterised by host tissue infarction and necrosis resulting from hyphae vasculature invasion, starting with a specific interaction with endothelial

cells.¹ The most common invasion route by the fungi is inhalation of spores in immunocompromised patients. It flourishes in tropical areas and the summer season. *Mucormycosis* has a high mortality and morbidity rate and, more often than not, is fatal.

The emergence of the COVID-19 pandemic has substantially increased the incidence of *mucormycosis* patients. Severe COVID-19 infections are associated with pro-inflammatory markers such as IL-1, IL-6, IL-6, and tumour necrosis alpha, less CD4 interferon-gamma expression, and fewer CD4 and CD8 cells that tend to increase the risk for bacterial and fungal infections.^{2,3} Corticosteroid Treatment, oxygen therapy and ventilatory support to patients admitted for treatment for COVID-19 have further given rise to these opportunistic infections. Even before COVID-19, *Mucormycosis* had a high incidence rate in India, possibly due to the high prevalence of Mucorales in the environment, which was only increased by the ensuing pandemic. The infection usually begins in the nasal cavity and tends to spread to paranasal sinuses.

* Corresponding author.

E-mail address: rkstent5@gmail.com (R. K. Singh).

Rhinocerebral *mucormycosis*, an invasion of the brain and orbit, involves sphenopalatine and internal maxillary arteries.⁴ Extension of the disease into the maxillary and ethmoid sinus can lead to orbital involvement. The involvement of the internal carotid and cavernous sinus has been seen in long-standing cases.⁵ Extension of the disease into the maxillary and ethmoid sinus can lead to orbital involvement. Intracranial spread can occur through the superior orbital fissure, ophthalmic vein and cribriform plate along the perivascular channels.

Signs and symptoms commonly seen in patients with *mucormycosis* are epistaxis, nasal obstruction, nasal ulceration, anaesthesia over the cheek and hard palate ulceration. Black necrotic eschar tissue is often observed in the nasal cavity in *mucormycosis* and is one of the most characteristic findings.⁶ The most common site involved in *mucormycosis* in the nasal cavity is usually the middle turbinate. Eye symptoms like decreased vision, redness of the eyes, diplopia, restriction of movement, ophthalmoplegia and complete loss of vision in one or both eyes. Patients with intracranial involvement often present with seizures, hemiparesis, cranial nerve palsy and altered sensorium. Rhino cerebral *mucormycosis* carries high overall mortality, with rates up to 46 % in patients with sinus involvement and 62 % in patients with rhino cerebral involvement.^{7,8}

We present a case series of 48 patients who underwent medical and surgical treatment for rhino-orbital *mucormycosis* and were histopathologically diagnosed for the same between May 2021 and August 2021 and our observation with different grades of the disease, the age group, presentation, co-morbidity status and personal hygiene profile of these patients. We intend to reiterate and highlight the importance of this highly ignored and almost fatal disease, which can create havoc and put the entire medical system to a standstill in times of pandemics like COVID-19, which can create additional immune suppression and allow these opportunistic fungi to grow unchecked.

2. Materials and Methods

A retrospective case series analysis was performed on 48 histopathologically diagnosed patients presenting to the ENT OPD for follow-up. These patients had undergone medical and surgical treatment at our institution between May 2021 and August 2021. A questionnaire was devised, which was used to collect detailed history pre and post the onset of *mucormycosis*. The parameters were the number of patients receiving oxygen therapy, history of suffering from COVID-19, history of farming and exposure to cattle, history of receiving ventilation in an intensive care unit (ICU) set-up, bathing habits, occupation, grade of the disease, history of diabetes mellitus, surgery performed on them and treatment received.

The pre-operative radiological scans of all the patients were analysed, the grade of the disease was noted, and the was performed. Written informed consent was obtained from each patient for their anonymised information to be published in this article. Ethics committee approval was taken for this study.

3. Results

In our case series of 48 patients diagnosed with *mucormycosis*, we observed that only 12 had received oxygen therapy while the other 36 did not (Table 1). Thirty-two of those patients tested positive for COVID-19, but the remaining 16 tested negative (66.6%). In our series of patients, we evaluated the history of farming and exposure to cattle, of which 54 % had a history of agriculture and exposure or contact with cattle, and 46% did not have any significant exposure to either. To assess whether *mucormycosis* was an ICU-related infection, we checked our data for previous ICU admissions. We found that 8 out of the 48 or 16.6 % of the total cases had a history of receiving ventilation in an ICU set-up. Longer ICU stay, use of corticosteroids, cross-contamination of microbes, and antibiotic resistance lead to opportunistic fungus (Figure 1).

35 out of 48 patients (72.9%) in our review bathed every day, and the most common occupation amongst them was homemakers or housewives (15), followed by farming (7). This was done to evaluate any common habit that might have been instrumental in causing these infections.

On grading the disease, with Grade 1 being the involvement of the nose, Grade 2 involvement of nose and paranasal sinuses, Grade 3 disease involving orbit and Grade 4 disease-causing intracranial involvement, we found 22 patients were Grade 2 at presentation, 22 Grade 3 and only 4 had Grade 4 disease (Figure 2). In our series, 20 out of these 48 patients underwent endoscopic debridement; on 15 open debridement, 11 patients had open debridement along with orbital exenteration performed on them. In contrast, the last 2 had endoscopic debridement with removal of the palate.

In terms of the history of diabetes mellitus, 16 never had any history of diabetes, 8 had type 2 DM diagnosed after testing positive for COVID-19 infection but before *mucormycosis* diagnosis and 20 suffered from the disease before COVID-19 as well. 4 of these patients were diagnosed with type 2 DM in the aftermath of *mucormycosis* (Table 2).

The most common age group of these patients was 45 years (7) patients, followed by 55(6) and 50 (5), bringing maximum patients between 45-55 years of age. The least common age group was below 25 years. Previous literature has put the most common age group as 45-60 years, which was also confirmed by our study.^{9,10}

Table 1: In our case series of 48 patients diagnosed with *mucormycosis*, we observed that only 12 had received oxygen therapy while the other 36 did not.

Received O2 Therapy	Total
NO	36
YES	12
Grand Total	48

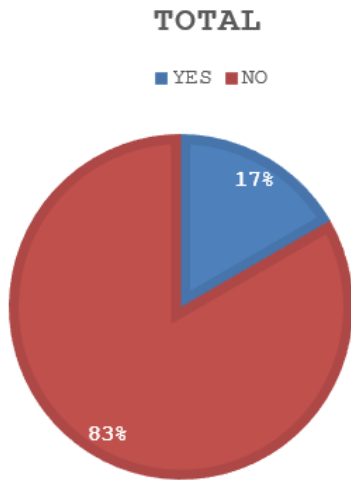


Figure 1: 8 out of the 48, or nearly 17 of the total cases, had a history of receiving ventilation in an ICU set-up

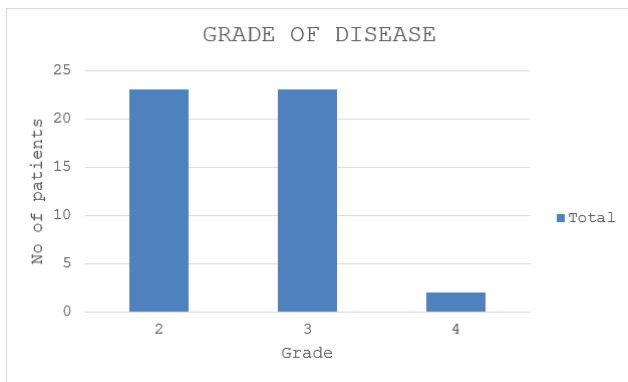


Figure 2: We found that 22 patients were Grade 2 at presentation, 22 were Grade 3, and only 4 had Grade 4 disease

Table 2: In terms of the history of diabetes mellitus, 16 never had any history of diabetes, 8 had type 2 DM diagnosed after testing positive for COVID-19 infection but before *mucormycosis* diagnosis, 20 suffered from the disease before COVID-19 as well. 4 of these patients were diagnosed with type 2 DM in the aftermath of *mucormycosis*.

History of type 2 diabetes mellitus	Total
Never had type 2 DM	16
DM after testing positive for COVID-19	8
Previous history of type 2 DM	20
Developed type 2 DM after mucor	4

4. Discussion

With the emergence of COVID-19, incessant use of steroids in patients recovering from the infection with comorbid conditions like Diabetes Mellitus has led to prolonged immunosuppression. It has increased the risk for diseases like invasive fungal aspergillosis and *mucormycosis*. The hyperglycaemia caused by DM has been further augmented by corticosteroid-induced hyperglycaemia. This is supported by our data of 20 out of 48 patients with pre-existing and diagnosed type 2 DM. This can essentially multiply immunosuppression in the patients and further the risk of opportunistic infections. Hyperglycaemia, acidosis and high-dose corticosteroid treatment paralyse phagocytes' ability and phagocytic functions, the principal host defence mechanism against *mucormycosis*, to immigrate to infected tissue and kill the organism. As the pH becomes acidic, the iron-protein complexes dissociate, allowing the fungal cells to use the increased free iron and proliferate. These infections remain largely inconspicuous and are difficult to identify due to the challenges posed by their diagnosis and the fact that non-covid healthcare was severely affected during the pandemic.^{11–13}

A thorough history is essential, including all COVID diagnosis and treatment details and diagnostic nasal endoscopy, which is mandatory in such cases. MRI PNS, Orbit and Brain were ordered for all suspected patients for pre-operative planning and accurate staging, as the limits of debridement will depend on the extent of the infection. The most common grades of disease were Grades 2 and 3, which suggested that the disease mainly involved the nose and paranasal sinuses. In rhino-orbital disease, debridement of the paranasal sinuses and peri-orbital tissues is the mainstay of surgical treatment and antifungal medications. ROCM may need to extend towards the skull base and cranium, requiring craniectomies and orbital exenteration. Revision surgeries may often be necessitated to control the infection.

At our centre, biopsy samples were sent for histopathological diagnosis, KOH mount, and GMS staining of the fungal debris. Neurosurgery consultations were done for all ROCM (Rhino-orbital-cranial *mucormycosis*) patients, and craniotomies were planned for the same. Liposomal Amphotericin B is the most widely accepted and prescribed treatment for *mucormycosis*, which was done for all 48 patients. Administration of this drug requires extensive surveillance of the kidney function. Second-line therapies may be added along with L-AMP-B. This can be combined with echinocandins and triazoles like Posaconazole or isavuconazole to increase the effectiveness of the treatment. Triazoles inhibit the 14- α - demethylation, leading to an increase in toxic 14- α -methyl sterols that alter the permeability of the fungal membrane. Patients who are intolerant to amphotericin B or there is a lack of availability of the same are given Posaconazole.^{14,15}

The management of this disease requires a multidisciplinary approach involving otolaryngology, medicine and its super specialities, neurosurgery, and anaesthesia departments. It is also one of those critical emergencies in otorhinolaryngology that can turn fatal in the blink of an eye and requires prompt response from everyone involved in patient care.

5. Clinical Significance and Conclusion

Mucormycosis is a disease that carries a high burden of morbidity and mortality. The high degree of suspicion in all patients with nasal, orbital or neuro complaints should be maintained with a previous history of COVID-19 infection and with or without comorbid conditions. Timely diagnosis and prompt treatment remain the pillars of its management. Often, the patient at first contact with healthcare facilities may have extensive disease. This requires awareness amongst the masses, especially those already suffering from diabetes mellitus or who have undergone kidney transplantations, as well as the health care workers. A multidisciplinary approach and aggressive antifungal treatment help in reducing the morbidity and mortality of this near-fatal condition.

6. Source of Funding

None.

7. Conflict of Interest

None.

8. Acknowledgement

We acknowledge the sincere efforts of our Anaesthesia, Neurosurgery, and Endocrine team, who provided round-the-clock assistance during the pandemic and surge in mucor cases.

References

1. Pilnis B, Alanio A, Lortholary O, Lanternier F. Recent advances in the understanding and management of mucormycosis. 2018;7:1–8.
2. Bhatt K, Agolli A, Patel MH, Garimella R, Devi M, Garcia E, et al. High mortality co-infections of COVID-19 patients: mucormycosis and other fungal infections. *Discov (Craiova)*. 2021;9(1):126.

3. Faraj SS, Jalal PJ. IL-6, and TNF- α cytokines cooperate to modulate a complicated medical condition among COVID-19 patients: case-control study. *Ann Med Surg (Lond)*. 2023;85(6):2291–7.
4. Kumar M, Alagarsamy R, Madi M, Pentapati KC. Rhinocerebral mucormycosis: a systematic review of case reports and case series from a global perspective. *Oral Surgery, Oral Medicine, Oral Pathology and Oral Radiology. Oral Surg Oral Med Oral Pathol Oral Radiol*. 2022;134(6):708–16.
5. Gelston CD, Durairaj VD, Simoes E. Rhino-orbital Mucormycosis Causing Cavernous Sinus and Internal Carotid Thrombosis Treated With Posaconazole. *Arch Ophthalmol*. 2007;125(6):848–9.
6. Lunge SB, Sajjan V, Pandit AM, Patil VB. Rhinocerebrocutaneous mucormycosis caused by Mucor species: A rare causation. *Indian Dermat Online J*. 2015;6(3):189–92.
7. Singh VP, Bansal C, Kaintura M. Sinonasal Mucormycosis: A to Z. *Indian J Otolaryngol Head Neck Surg*. 1962;71(3):1962–71.
8. Sharma A, Goel A. Mucormycosis: risk factors, diagnosis, treatments, and challenges during COVID-19 pandemic. *Folia Microbiol (Praha)*. 2022;67(3):363–87.
9. Wolthers MS, Schmidt G, Gjørup CA, Larsen JH, Rubek N, Jensen LT, et al. Surgical management of rhinocerebral mucormycosis: A case series. *JPRAS Open*. 2021;30:33–7.
10. Chavda VP, Apostolopoulos V. Mucormycosis - An opportunistic infection in the aged immunocompromised individual: A reason for concern in COVID-19. *Maturitas*. 2021;154:58–61.
11. Ahmed KK, Hashemi S. The double-edged sword of systemic corticosteroid therapy in viral pneumonia: A case report and comparative review of influenza-associated mucormycosis versus COVID-19-associated mucormycosis. *Mycoses*. 2021;64(8):798–808.
12. García-Carnero LC, Hm MM. Mucormycosis and COVID-19-Associated Mucormycosis: Insights of a Deadly but Neglected Mycosis. *J Fungi (Basel)*. 2022;8(5):445.
13. Kontoyiannis D, Lewis R. Invasive Zygomycosis: Update on Pathogenesis, Clinical Manifestations, and Management. *Infect Dis Clin North Am*. 2006;20:581–607.
14. El-Baky A, Shady RM, Yahia ER, R. COVID-19 associated Mucormycosis among ICU patients: risk factors, control, and challenges. *AMB Express*. 2023;13:99.
15. Teixeira MM, Carvalho DT, Sousa E, Pinto E. New Antifungal Agents with Azole Moieties. *Pharmaceuticals (Basel)*. 2022;15(11):1427.

Author biography

Shruti Jha, Senior Resident

Mani Mala, Junior Resident

Rakesh Kumar Singh, Professor and HOD

Cite this article: Jha S, Mala M, Singh RK. *Mucormycosis* during the COVID-19 pandemic: Our takeaways. *IP J Otorhinolaryngol Allied Sci* 2024;7(2):31-34.